Wound Measurement & Documentation Guide



Measuring Wounds

Measure the length "head-to-toe" at the longest point (A). Measure the width side-to-side at the widest point (B) that is perpendicular to the length, forming a "+". Measure the depth (C) at the deepest point of the wound. *All measures should be in centimeters.*

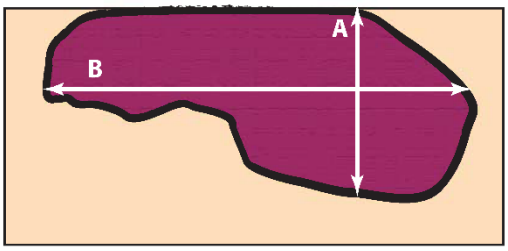

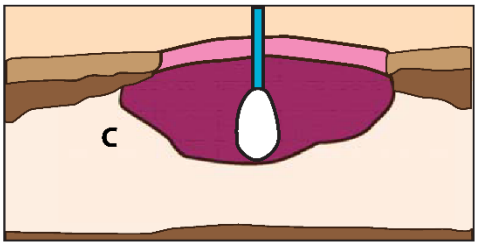

This ruler is intended for use as a reference only. To prevent infection, do not use this ruler to measure an actual wound.

Tunneling/Sinus Tract

A narrow channel or passage-way extending in any direction from the base of the wound. This results in dead space with a potential risk for abscess formation.

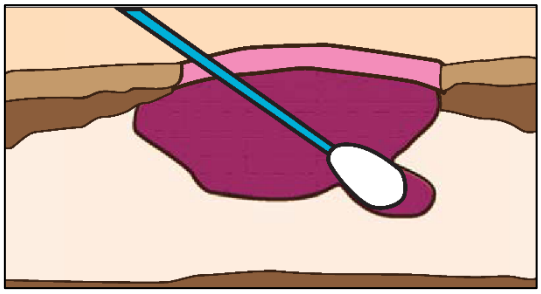

Using a clock format, describe the location and extent of tunneling (sinus tract) and/or undermining.

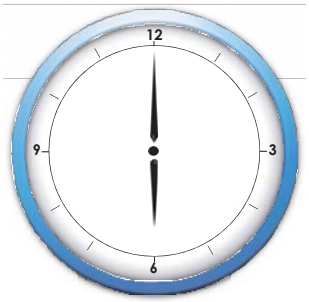

The head of the patient is 12:00, the patient's foot is 6:00.

Undermining

Open area extending under intact skin along the edge of the wound.

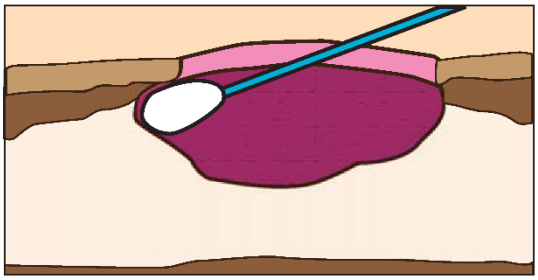

If the wound has many landmarks, you may want to trace it before measuring.

Quality Improvement Organizations
Sharing Knowledge. Improving Health Care.
CENTERS FOR MEDICARE & MEDICAID SERVICES
HQIN
Health Quality Innovation Network

Wound Measurement & Documentation Guide

Pressure Ulcer Documentation

Wound Location:

- Designate left, right, top, bottom, side, front, middle, etc., as appropriate(for example, inner left knee)
- Describe anatomical location according to your facility practice; abdomen,knee, coccyx, sacrum, trochanter (hip), ischial tuberosity (buttock), calcaneus (heel), malleolus (ankle), etc.

Be specific! Location description should direct staff to exact area for treatment.

Stage:

1, 2, 3, 4, suspected deep tissue injury (sDTI), unstageable

Size:

L x W x D

- Length (head-to-toe)
- Width (hip-to-hip)
- Depth (deepest point)

Exudate/Drainage:

Amount

- None, dry, scant, moist, small, medium,large, copious

Color

- Serous (thin, watery, clear)
- Sanguineous (bright red)
- Serosanguineous (thin, watery, pale red to pink)
- Purulent (thick or thin, opaque to tan to yellow or green)

Odor

- None, foul, pungent, fecal, musty, sweet

Wound Edges:

- Attached/unattached
- Undermining (use clock to designate location)
- Rolled under (epibole)
- Callused

Wound Base:

- Granulation (beefy red, bumpy in appearance)
- Epithelialization (light to deep pink, pearly light pink; may form islands in the wound bed)
- Necrotic Tissue
  - » Slough - thin stringy consistency; yellow, gray, white, green, brown
  - » Eschar - thick hard consistency; leathery, brown to black
  - » Adherency - Non-adherent, loosely adherent, firmly adherent
- Tunneling/Sinus Tract (use clock to designate location)

Surrounding Skin:

- Color (red, pink, pallor, purple, normal skin tones)
- Edema; pitting, non-pitting
- Firmness (induration)
- Temperature (warmer or cooler than adjacent skin)
- Other Characteristics: intact, macerated,rash, excoriated, etc.

Pain Assessment:

- Rate on scale of 1-10 before, during and after treatment; episodic or chronic
- Interventions for pain

Wound Progress:

- Improving, deteriorating, no change
- Interventions in place: pillows, low airloss beds, special devices, nutritional supplements, etc.
- Continued treatment **or** notify MD and responsible party of need for treatment change

Quality Improvement Organizations
Sharing Knowledge. Improving Health Care.
CENTERS FOR MEDICARE & MEDICAID SERVICES
HQIN
Health Quality Innovation Network